

# Eye movements in patients with neurodegenerative disorders

Tim J. Anderson and Michael R. MacAskill

**Abstract** | The neural pathways and brain regions involved in eye movements during ocular fixation and gaze control include the cerebrum, brainstem and cerebellum, and abnormal eye movements can indicate the presence of neurodegeneration. In some patients, oculomotor signs are key to making a diagnosis. Careful clinical examination of eye movements in patients with neurodegenerative disorders is, therefore, an invaluable adjunct to neurological and cognitive assessments. Eye movement recordings in the laboratory are generally not necessary for diagnostic purposes, but can be a useful addition to the clinical examination. Laboratory recordings of eye movements can provide valuable information about disease severity, progression or regression in neurodegenerative disease, and hold particular promise for objective evaluation of the efficacy of putative neuroprotective and neurorestorative therapies. For example, aspects of saccade performance can be tested to probe both motor and cognitive aspects of oculomotor behaviour. This Review describes the oculomotor features of the major age-related movement disorders, including Parkinson disease, Huntington disease, dementia and other neurodegenerative disorders. Findings in presymptomatic individuals and changes associated with disease progression are discussed.

Anderson, T. J. & MacAskill, M. R. *Nat. Rev. Neurol.* advance online publication 22 January 2013; doi:10.1038/nrneurol.2012.273

## Introduction

Eye movements generally fall into two classes. One class of movements includes rotational and translational vestibulo-ocular reflexes (VORs), fixation, smooth pursuit and optokinetic nystagmus, which stabilize the fovea in relation to movement of the body or of objects in the surrounding environment. Humans use a second kind of eye movement (the saccade) to rapidly shift the fovea and bring its superior acuity and colour sensitivity to bear on objects of interest. Saccades are an inherent part of the constant cycle of perception, action and cognition. Several of these movements are made each second throughout the waking day, and they are our most common form of voluntary behaviour.<sup>1</sup> All forms of eye movements are subject to disruption in various neurological conditions, but saccades are of particular interest because the close link between saccades and attention<sup>2</sup> means that they are likely to be disturbed by cognitive impairments associated with neurodegenerative disorders, as well as by dysfunctions related purely to oculomotor execution.

In this Review, we focus predominantly on the most common age-related cerebral neurodegenerative diseases (Table 1), which vary in the degree to which they affect motor, cognitive and behavioural processes. For example, patients in the early stages of Parkinson disease (PD) or multiple system atrophy (MSA) have mostly motor abnormalities, whereas patients with early Alzheimer disease (AD) tend to have only cognitive manifestations.

In other neurodegenerative conditions, such as progressive supranuclear palsy (PSP) and Huntington disease (HD), patients might have a combination of motor, cognitive and/or behavioural features, even in the earliest stages of disease (Figure 1). Neurodegenerative diseases also evolve over time, such that in patients with PD, for example, cognitive impairment and dementia frequently accrue until they are the main symptoms.<sup>3</sup> Eye movements that are used for monitoring of disease progression, therefore, need to be sensitive to both motor and cognitive disease processes.

For diagnosis of a neurological disorder, careful clinical oculomotor examination is usually adequate, and adjunctive laboratory eye movement measurements do not usually add much relevant information. Generally, clinical examination aims to identify oculomotor abnormalities that frequently represent, or are an amplification of, the underlying somatomotor features of the disorder; for example, gaze-evoked nystagmus is evidence of cerebellar involvement in patients with MSA.<sup>4</sup> By contrast, laboratory eye movement recordings are most useful for objective and precise identification of disease status and monitoring of disease progression. The advantage of laboratory recordings, particularly of saccades, over clinical examination is that recordings enable cognitive as well as motor impairments associated with neurodegeneration to be detected. For example, in patients with PSP, excessive square wave jerks and slow saccades—useful diagnostic features—can be detected by both clinical and laboratory assessments.<sup>5</sup> However, increased error rate of antisaccades, which indicates

Department of Medicine, University of Otago Christchurch, 2 Riccarton Avenue, Christchurch 8011, New Zealand (T. J. Anderson). New Zealand Brain Research Institute, 66 Stewart Street, Christchurch 8011, New Zealand (M. R. MacAskill).

Correspondence to T. J. Anderson [tim.anderson@otago.ac.nz](mailto:tim.anderson@otago.ac.nz)

## Competing interests

The authors declare no competing interests.

**Key points**

- Careful clinical examination of eye movements is a useful adjunct in the diagnosis of many neurodegenerative disorders; laboratory eye movement recordings do not usually provide diagnostic clues
- Different saccadic paradigms and laboratory recordings precisely reflect cognitive and motor characteristics of neurodegenerative disorders and may be useful biomarkers of disease severity and progression, especially in dementia
- Clinical oculomotor examination in Parkinson disease indicates subtle saccadic hypometria and mildly impaired smooth pursuit, whereas laboratory recordings show voluntary saccadic abnormalities that correlate with cognitive status
- Atypical parkinsonian disorders are associated with distinctive features: slowed saccades in progressive supranuclear palsy, positional and head-shaking downbeat nystagmus in multiple system atrophy, and saccadic apraxia in corticobasal syndrome
- Specific oculomotor hallmarks that aid diagnosis in spinocerebellar ataxia (SCA) are very slowed saccades in SCA2 and SCA7, positional downbeat nystagmus in SCA6, and hypoactive vestibulo-ocular reflex in Friedreich ataxia
- Future work is needed to explore the robustness and repeatability of laboratory eye movement recordings in healthy controls and disease states

cognitive dysfunction, can only be detected in the laboratory. Although impaired antisaccade performance can be detected clinically,<sup>6</sup> it is best quantified using recordings of eye movements in the laboratory.<sup>7</sup> The clinical and laboratory oculomotor features of many neurodegenerative diseases have been well characterized in the past 20 years, and are now being used to monitor presymptomatic individuals—for example, those with HD—and disease progression.<sup>8–10</sup>

In this Review, we provide a brief overview of eye movement tasks, and discuss the oculomotor features of the main age-related movement disorders, including PD and HD, dementia and other important neurodegenerative disorders. Findings of relevance to presymptomatic (preclinical) disease are also described. Assessment of oculomotor abnormalities can also be useful for diagnosis of a range of other diseases associated with parkinsonism, movement disorders, or dementia, but a detailed discussion of these disorders is outside the scope of this Review.

**Eye movement tasks**

Understanding the oculomotor research literature requires some familiarity with the taxonomy of eye movement tasks used in the laboratory. The simplest saccade assessment uses the reflexive paradigm (also known as the visually guided paradigm), in which the participant is directed to look at a target as soon as it flashes at a new random location on a screen. Subtle manipulation of the stimulus (such as inserting either a temporal gap or overlap between successive target appearances) can be used to test inhibitory processes. Such a gap between visual stimuli results in decreased activity of neurons in the superior colliculus, which are responsible for maintenance of gaze fixation, allowing a subsequent saccade to occur sooner.<sup>11</sup> This temporal gap allows the investigator to systematically influence the latency of saccades without the participant needing to learn or even be aware of the changed demands of the task.

Other saccade tasks require more cognitive processing. In the memory-guided paradigm, for example, a target flashes briefly on a screen and the participant must first suppress a reflexive saccade towards it, waiting until a second cue. Only then should a voluntary saccade be made to the location of the no-longer-visible target, guided by the patient's memory of its location. Although memory-guided saccades might seem to be a highly artificial (that is, laboratory-only) situation, they are probably more the rule than the exception in real-world behaviour, in which reflexive saccades are likely to be made only rarely.<sup>12</sup> As an illustration, we are far more likely to look at a clock on the wall because we remember that is where to find out the time, than because a movement of the clock hands reflexively caught our attention.

Other eye movement tasks, such as suppressing a saccade towards a target and instead looking in the opposite direction (the antisaccade), or following targets that alternate regularly between two locations at a fixed rate (predictive saccades), are not likely to be experienced outside the laboratory. These relatively simple tasks, however, enable researchers to probe various cognitive processes, which can be assessed by behavioural measures (such as saccade accuracy and latency) or functional brain imaging.

The stimuli used in neurological studies of eye movements—namely, small jumping-point targets that enable precise measurement of the latency and accuracy of the movements—are typically impoverished compared with those in real-world situations. Whether the deficits observed in individuals in response to these controlled stimuli can be measured in more naturalistic eye movement tasks, and how such deficits influence patients' functioning in real-world situations, is being investigated in patients with PD, as discussed below.

**The parkinsonian disorders****Parkinson disease**

Neurophysiological studies in monkeys have confirmed that the substantia nigra pars reticulata is involved more in voluntary saccade tasks than in visually guided eye movements, and that output of this region has an inhibitory effect on saccade amplitude.<sup>13</sup> The inhibitory output from the substantia nigra pars reticulata (which acts on the saccade-triggering structure, the superior colliculus) is overactive in patients with PD. This increased inhibition might, therefore, be expected to cause characteristic impairment of saccades even early in the course of the disease.

Quantitative measurement of saccades in patients with PD began in the 1960s, but until 2011<sup>14,15</sup> the majority of published studies of this technique have had low numbers of participants. The resulting lack of statistical power, and the well-known heterogeneity of presentation of this disease, has led to inconsistency in the findings of these studies. For example, the latency of saccades to predictably alternating targets in patients with PD has been characterized as abnormally prolonged,<sup>16,17</sup> normal,<sup>18</sup> or reduced<sup>19</sup> versus that in controls. Conflicting results have

**Table 1** | Eye movement abnormalities in neurodegenerative disorders

Neurodegenerative disorder	Eye movement characteristics found in the clinic	Eye movements recorded in the laboratory
<b>Lewy body parkinsonian diseases</b>		
Parkinson disease	Mild hypometria of upwards voluntary saccades Mildly impaired smooth pursuit	↓ Gain (hypometria) of voluntary saccades
Parkinson disease dementia	Not reported	↑ Latency and ↓ gain of reflexive and (particularly) voluntary saccades ↑ Antisaccade errors
Dementia with Lewy bodies	Supranuclear gaze palsy in some patients (case reports)	↑ Latency of reflexive and voluntary saccades ↓ Saccade prediction ↑ Antisaccade errors ↓ Express saccades (in the gap task)
<b>Huntington disease</b>		
Symptomatic patients	Apraxia of saccades (difficulty with initiation) with or without head thrusting Slow saccades, especially in patients with young age at onset Gaze distractibility and impersistence	↑ Saccade latency ↑ Variability of saccade latency ↓ Saccade velocity ↑ Directional and timing errors of antisaccades and memory-guided saccades Distractibility during smooth pursuit
Presymptomatic patients	Normal	↑ Saccade latency ↑ Variability of saccade latency ↑ Antisaccade and memory-guided saccade errors
<b>Dementia</b>		
FTD	Not reported, but patients who progress to PSP or corticobasal syndrome exhibit eye movement abnormalities characteristic of those disorders	Normal reflexive saccades ↑ Antisaccade errors (in patients with behavioural variant FTD and PNFA) that are corrected normally Normal antisaccades (in patients with semantic dementia)
Alzheimer disease	Impaired visual grasp reflex on clinical antisaccade test	↑ Fixation instability ↑ Latency of reflexive and voluntary saccades ↑ Antisaccade errors ↓ Correction of antisaccade errors

Abbreviations: FTD, frontotemporal dementia; PNFA, progressive nonfluent aphasia; PSP, progressive supranuclear palsy.

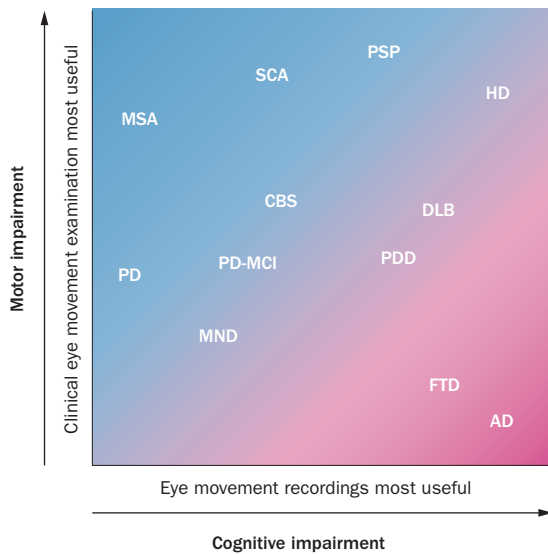
also been found for saccade testing using simple visually guided paradigms, although a meta-analysis of 47 studies revealed an overall trend towards slightly prolonged saccade latency in patients with PD compared with controls.<sup>20</sup> By contrast, impaired initiation of saccades in cognitively demanding experimental tasks, such as memory-guided saccades and antisaccades, has been found fairly consistently in this setting. Researchers generally agree, however, that saccade amplitude is decreased in patients with PD—subtly in tests using simple visually guided paradigms, but substantially in cognitively demanding visual tasks (Figure 2).

Decreased saccade amplitude can be detected even in clinical examinations of patients with PD by observing the amplitude of saccades that are made in response to irregular verbal commands to look repeatedly between two of the examiner's fingers. The amplitude of saccades is visibly reduced when the patient is then asked to execute the same movements repetitively at their own volition (R. J. Leigh, personal communication). Laboratory recordings (Figure 2) enable the degree of this task-specific hypometria to be quantified. In patients with PD, reduced saccade amplitude is detectable early in the disease course, presumably reflecting degeneration

in the basal ganglia, given that higher-level eye movement related areas are yet to be affected. By contrast, increased saccade latency occurs later in the disease course<sup>14</sup> and is associated with cognitive impairment.<sup>15,21</sup> Increased saccade latency might, therefore, be driven by the widespread nondopaminergic neural dysfunction that occurs later in the disease.

Some researchers have made recordings from patients with PD while the patients inspected line drawings of varying complexity.<sup>22</sup> Their spontaneous visual scanning patterns showed characteristic deficits associated with PD: reduced-amplitude saccades and prolonged fixation intervals, which resulted in a smaller region of each image being inspected by patients than by controls. Moreover, other studies showed that altered eye movement scanning strategies might contribute to impaired judgement of facial emotions in patients with PD.<sup>23</sup>

Of perhaps greater clinical relevance than these laboratory studies, the role of eye movements in guidance and initiation of body turns has been investigated in patients with PD.<sup>24–26</sup> The risk of falling is elevated during turns, particularly for patients with PD who have freezing of gait. In healthy individuals, turning is characterized by an orderly sequence of rotations, beginning



**Figure 1** | Variation in the extent of motor and cognitive impairment and the role of eye movement assessments in age-related neurodegenerative disorders. Clinical oculomotor examination is most useful as an aid to diagnosis of disorders with primarily motor symptoms and little cognitive impairment (for example, MSA). Laboratory-based assessment of eye movements, particularly testing of saccade characteristics, is most useful to monitor disease stage in patients with disorders dominated by dementia and little motor impairment (for example, AD). For conditions in which cognitive and motor features are both prominent (for example, HD and PSP), clinical oculomotor examination is useful for diagnosis, whereas laboratory recordings might be more appropriate in tracking disease status and progression. Abbreviations: AD, Alzheimer disease; CBS, corticobasal syndrome; DLB, dementia with Lewy bodies; FTD, frontotemporal dementia; HD, Huntington disease; MND, motor neuron disease; MSA, multiple system atrophy; PD, Parkinson disease; PD-MCI, Parkinson disease with mild cognitive impairment; PDD, Parkinson disease dementia; PSP, progressive supranuclear palsy; SCA, spinocerebellar ataxia.

with saccades and followed in turn by the head, the trunk, and finally the feet, whereas in patients with PD, this sequence is compressed to produce an *en bloc* turn.<sup>25</sup> Saccades in patients with PD are decreased in amplitude, so that larger numbers of saccades are needed in preparation for turning, which correlates with increased duration for the entire body turn.<sup>26</sup> Patients with PD also showed an increase in the interval between the first saccade and the initiation of body movement, although they also showed evidence of compensatory saccade strategies. For example, the initial saccade was made earlier in patients with PD than in healthy controls, perhaps to compensate for the subsequent axial delays.<sup>26</sup> The proportion of gaze shifting contributed by eye movements (rather than head and trunk movements) was higher in patients with PD than in controls, perhaps in compensation for the increased impairment of head and trunk movement.<sup>24</sup>

In summary, findings on clinical examination of eye movements in patients with PD are only subtly abnormal. Some mild hypometria of voluntary, and

particularly upward, saccades is consistent with a diagnosis of PD, but any other clinically evident eye movement abnormality should raise suspicion of an atypical parkinsonian disorder. In clinical practice, minor impairments in other oculomotor modalities (Figure 3), such as smooth pursuit, VOR suppression and optokinetic nystagmus are difficult to distinguish from the effects of normal ageing. In the laboratory, the consistent distinguishing feature of PD is hypometria of voluntary eye movements, such as predictive and memory-guided saccades, and of antisaccades. In patients with PD and cognitive impairment, increased latency of reflexive and—especially—voluntary saccades is additionally encountered in laboratory examinations, and the extent of latency increase correlates with disease severity. None of the studies discussed in this section, however, include data from patients with autopsy-proven PD, so the results should be viewed with caution.

**Parkinson disease with dementia**

Most patients with PD develop mild cognitive impairment that eventually progresses to dementia.<sup>27</sup> However, clinical studies of eye movement abnormalities, have not been conducted in such patients. The only two published reports of eye movement assessments in the laboratory showed increased latency and diminished gain of reflexive saccades in patients with Parkinson disease with dementia (PDD), compared to both controls and patients with PD who do not have cognitive impairment.<sup>15,21</sup> In voluntary eye movement tasks, patients with PDD made fewer predictive saccades and had impaired saccade suppression (inhibition).<sup>21</sup> Our research group has shown that patients with PD and mild cognitive impairment (PD-MCI) have similar saccade abnormalities to those of patients with PDD, although to a lesser extent, and that saccade abnormalities in patients with PD-MCI are correlated with global motor and cognitive ratings, as they are in patients with PDD.<sup>15</sup>

Early studies on the influence of cognitive status on saccade performance in parkinsonian diseases showed that impairments in reflexive saccade execution and complex saccade performance were greater in patients with PDD or dementia with Lewy bodies (DLB) than in patients with cortical forms of dementia (such as AD) alone, or PD without cognitive impairment.<sup>21</sup> Perhaps as a result of these findings, researchers increasingly use neuropsychological assessment to quantify the effect of cognitive function on saccade performance.<sup>15,28,29</sup> For example, relationships have been found between the speed of saccade initiation and verbal fluency tasks involving identification of letters or animals.<sup>30</sup>

**Dementia with Lewy bodies**

No systematic clinical oculomotor investigations have been undertaken in patients with DLB, but a small number of case reports describe patients who present with vertical (with or without horizontal) gaze palsies and greater impairment in upward gaze than in downward gaze.<sup>31</sup> Laboratory investigations of eye movements in patients with DLB show similar abnormalities

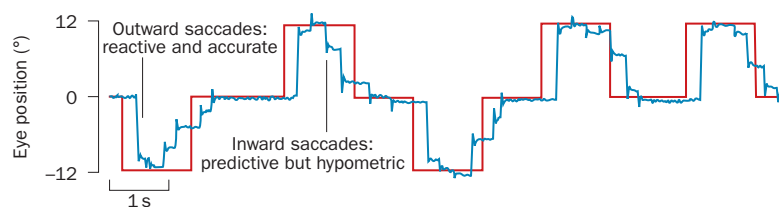
to those of patients with PDD, with prolonged latency of all types of horizontal saccade, impaired predictive saccades and impaired saccade suppression.<sup>21,32</sup> Detailed examination of horizontal and vertical saccades in 10 patients with DLB revealed reduced tendency for these patients to make express (that is, short-latency of 80–130 ms) saccades in the gap task—a version of the visually guided paradigm, in which the gaze-fixation target is removed shortly before the saccade target appears. The patients also showed reduced velocity and accuracy, and increased variability, of both horizontal and vertical saccades.<sup>32</sup> As in patients with PD-MCI and PDD, individuals with DLB show increased latency of both reflexive and—especially—voluntary saccades, the extent of which correlates with disease severity. In some patients with DLB, vertical supranuclear gaze palsy is evident (Table 1).

### Multiple system atrophy

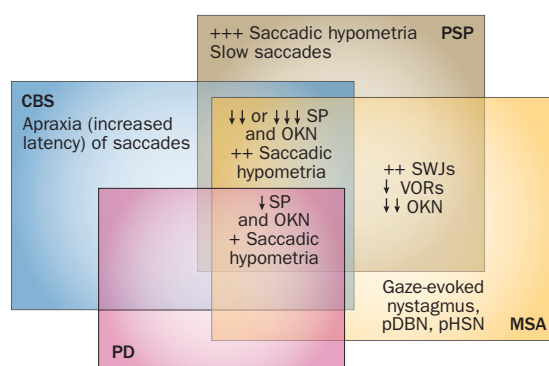
MSA is an  $\alpha$ -synucleinopathy that comprises two phenotypes: MSA with predominant parkinsonism (MSA-P) and MSA with predominant cerebellar ataxia (MSA-C). Eye movement abnormalities in patients with MSA reflect the underlying pathology of cell loss and gliosis in the striatonigral and olivopontocerebellar systems, which is common to both phenotypes. Patients with MSA-C usually present with symptoms that suggest a late-onset cerebellar syndrome associated with typical cerebellar eye signs such as gaze-evoked, downbeat and rebound nystagmus, and impaired smooth pursuit.<sup>33</sup> By contrast, MSA-P can be difficult to distinguish from PD and other parkinsonian disorders. Most patients with MSA-P, however, have increased square wave jerks,<sup>4,34,35</sup> mild or moderate saccade hypometria<sup>4,35–37</sup> and impairment of VOR suppression and smooth pursuit on clinical oculomotor examination.<sup>4,35,38,39</sup> This combination of eye movement abnormalities is not found in patients with PD.

Saccade velocities are normal in patient with MSA-P and only a minority of such patients have mild vertical supranuclear gaze palsy on clinical examination.<sup>4</sup> Specific tests can unmask cerebellar oculomotor involvement in patients with MSA-P who do not have clinical cerebellar disease manifestations. Positional downbeat nystagmus, which may show habituation, is present in ~30% of patients with MSA, including some without cerebellar signs of disease.<sup>4,40</sup> Similarly, perverted head-shaking nystagmus (vertical nystagmus on horizontal head oscillation) is present in ~35% of patients with MSA-P.<sup>40</sup> The above studies contained few or no autopsy-proven cases of MSA-P, however, calling for caution in interpretation of results.

In summary, clinical examination of patients with suspected MSA should focus on detection of excessive square wave jerks, moderate saccade hypometria, moderate impairment of smooth pursuit and VOR suppression, as well as cerebellar oculomotor features such as nystagmus (gaze-evoked, positional downbeat or head-shaking forms). The presence of slow saccades or prominent supranuclear gaze palsy suggests a diagnosis



**Figure 2** | Task-specific saccade hypometria in a patient with Parkinson disease. The visual stimulus, shown as a red line, was initially located at the centre of the screen (0°), and then moved at irregular intervals to the left (downwards) and to the right (upwards). After a constant interval, the stimulus returned to the point of central fixation. The patient's eye movements (blue line) show slight hypometria (but still within the normal range) in response to the unpredictable outward movements of the stimulus. The return inward movements of the stimulus were predictable, as indicated by the initiation of saccades before the target had moved. The patient's predictive saccades are severely hypometric and have a multistep pattern characteristic of voluntary saccades in patients with Parkinson disease.



**Figure 3** | Patterns of eye movement abnormalities in parkinsonian disorders. Some features are shared, whereas others are specific to particular disorders. Abbreviations: ↓, mildly impaired; ↓↓, moderately impaired; ↓↓↓, severely impaired; +, mild; ++, moderate; +++, severe; CBS, corticobasal syndrome; MSA, multiple system atrophy; OKN, optokinetic nystagmus; PD, Parkinson disease; pDBN, positional downbeat nystagmus; pHSN, perverted head-shaking nystagmus; PSP, progressive supranuclear palsy; SP, smooth pursuit; SWJs, square wave jerks; VORs, vestibulo-ocular reflex suppression. Permission obtained from John Wiley and Sons © Anderson, T. J. *et al. Mov. Disord.* **23**, 977–984 (2008).

other than MSA.<sup>4</sup> Laboratory recordings of eye movements in patients with MSA-P do not usually provide additional diagnostic information, but can reinforce the clinical findings.

### Progressive supranuclear palsy

PSP is a tauopathy that has three principal syndromic presentations: the classic Richardson syndrome, PSP with parkinsonism (PSP-P),<sup>41</sup> and the rare PSP with pure akinesia and gait freezing (PSP-PAGF).<sup>42</sup> Some clinicians also include two other syndromes: PSP with corticobasal syndrome and PSP with progressive nonfluent aphasia (PSP-PNFA), which are discussed in other sections of this article.<sup>43</sup>

The earliest—and, therefore, most diagnostically important—oculomotor feature in patients with Richardson syndrome is slowing of vertical saccades, although horizontal saccadic slowing also develops later

in the disease course.<sup>5,35,37,44–48</sup> Slowing of downward saccades is considered the hallmark of this condition, and is included in the diagnostic criteria,<sup>49</sup> but the velocity of upward saccades is reduced by at least as much, and in some patients more so.<sup>5</sup> Most patients eventually lose the ability to perform saccades and smooth pursuit, although this failure is largely overcome by the VOR—a compensation that indicates a supranuclear gaze palsy. In fact, upward gaze palsy occurs more frequently than downward gaze palsy in patients with Richardson syndrome.<sup>5</sup>

During clinical optokinetic nystagmus testing in Richardson syndrome, the patient's eyes might tonically drift in response to the visual cue in the direction of the slow phase of the nystagmus indicating the loss of reflexive saccades.<sup>37,50</sup> Patients with advanced disease can have complete ophthalmoplegia.<sup>51</sup> Vertical and horizontal saccades become markedly hypometric, and smooth pursuit is at least moderately impaired.<sup>44</sup> Fixation instability with small-amplitude horizontal square wave jerks is more prominent than in other parkinsonian disorders.<sup>34,52</sup> Moreover, markedly diminished blink rate, and eye-opening and eye-closing apraxia are frequently present. In the laboratory, slowing of vertical saccades to a greater extent than slowing of horizontal saccades is the key distinguishing feature of Richardson syndrome,<sup>5</sup> and the extent of slowing of vertical saccades correlates with dorsal midbrain volume.<sup>48</sup> Other findings are increased latency of vertical reflexive saccades,<sup>7,48</sup> accompanied by saccade hypometria, a high percentage of errors on antisaccade tasks,<sup>48,53,54</sup> and markedly impaired smooth pursuit.<sup>35</sup> As for other syndromes discussed in this article, these observations are derived primarily by studies in patients with a clinical diagnosis of PSP, rather than autopsy-proven PSP.

Eye movements in patients with PSP-P and PSP-PAGF have not been studied specifically, and information about eye movement abnormalities in such patients generally comes from postmortem retrospective reports. Visual problems, are less common in patients with PSP-P than with Richardson syndrome, and supranuclear gaze palsy is usually absent during early PSP-P, but develops late in the disease course in 70% of patients.<sup>41</sup> In patients with PSP-PAGF, by definition supranuclear gaze palsy is not seen in the first 5 years after disease onset—and might never develop in some patients—but can occur as a late disease feature, together with blepharospasm.<sup>42</sup>

To summarize, on clinical examination, slowing of vertical saccades can suggest a diagnosis of PSP (and help to rule out PD, MSA or corticobasal syndrome). A marked excess of small-amplitude square wave jerks, hypometria of vertical and horizontal saccades and moderately impaired smooth pursuit also suggest this diagnosis. Laboratory recordings of eye movements can confirm the clinical findings, especially those of saccade slowing and increased small-amplitude square wave jerks, and typically also reveal increased antisaccade errors—a feature that is not seen in PD or MSA. Antisaccade errors are, however, also found in patients with other types of dementia and corticobasal syndrome, as discussed below.

## Corticobasal syndrome

Various pathologies can underlie a clinical presentation of corticobasal syndrome, including not only corticobasal degeneration, but the associated pathology of PSP, Pick disease, AD, DLB and Creutzfeldt–Jakob disease.<sup>42,55,56</sup> The oculomotor hallmark of clinically diagnosed corticobasal syndrome is saccade apraxia,<sup>37</sup> which is clinically observed as difficulty and delay in the initiation of saccades towards a target, and in the laboratory as a substantial increase in saccade latency.<sup>47,57,58</sup> Other findings on eye examination in the laboratory are antisaccade errors similar to those seen in patients with PSP.<sup>7,48,53,54,57</sup> Smooth pursuit can also be moderately impaired in patients with corticobasal syndrome, but usually not as severely as in patients with PSP. In contrast to PSP, saccade velocities in patients with corticobasal syndrome are normal.<sup>7,48</sup>

In a prospective study of a series of patients, increase in saccade latency was present in only one of four patients with autopsy-confirmed corticobasal degeneration.<sup>48</sup> In a retrospective study, gaze palsy was seen in only 20% of patients early in the disease course, and in one-third of patients at later stages of disease, although increased latency or saccade apraxia was not specifically mentioned.<sup>59</sup> In a separate study, the investigators suggested that patients with presumed early-onset corticobasal syndrome (not autopsy-proven) and prolonged saccade latencies or saccade apraxia might have underlying AD pathology.<sup>48</sup> Clarification of the prevalence and pathophysiological substrate of saccade apraxia in patients with corticobasal syndrome requires prospective studies of eye movement records from patients with subsequent autopsy-proven diagnosis is needed.

In summary, saccade apraxia is the key abnormality detected in clinical examination of eye movements in patients with corticobasal syndrome. Laboratory recordings of eye movements are useful to confirm increased latency of saccades (especially voluntary saccades) and to confirm the normal velocity of saccades in patients with corticobasal syndrome, which contrasts with the slow saccades observed in patients with PSP. Such recordings also tend to show an increase in antisaccade errors, which are also common in patients with PSP and the dementias, but are not observed in patients with PD or MSA.

## Huntington disease Symptomatic individuals

Overt HD is characterized by saccade apraxia, especially in response to a verbal instruction rather than a visual cue. Saccade apraxia can be accompanied by head-thrusting movements, distractibility and impersistence of gaze, and reduced velocity of saccades.<sup>60,61</sup> Vertical saccades are usually affected more than horizontal saccades, although in our clinical experience, some patients with HD have more slowing of horizontal saccades than of vertical saccades. Additional clinical findings include saccade hypometria—again, affecting vertical saccades more than horizontal ones—and mild or moderate impairment of smooth pursuit. Slowing of saccades is

prominent in patients with early-onset HD—the so-called Westphal variant, in which bradykinesia and rigidity predominate.<sup>60,61</sup> Laboratory recordings of eye movements typically show increased saccade latency,<sup>62–65</sup> marked variability in saccade latency,<sup>62,64</sup> and saccade slowing, which affects vertical saccades to a greater extent than horizontal ones.<sup>60–63,66</sup> Increased directional errors and timing errors affecting antisaccades and memory-guided saccades<sup>8,62,67,68</sup> are also more evident for vertical than horizontal saccades.<sup>64</sup> Patients also have increased distractibility of gaze during smooth pursuit.<sup>69</sup> The extent of the reduction in the velocity of saccades,<sup>63</sup> variability in latency,<sup>62,65</sup> and saccade errors<sup>8,62,68</sup> correlates with disease severity.

In summary, the key oculomotor features that are clinically detectable in patients with symptomatic HD are saccade apraxia (sometimes associated with head thrusting) and slowing of saccades; such slowing is particularly prominent in patients with a young age at onset of symptoms. Laboratory recordings of eye movements can confirm prolonged saccade latency and saccade slowing in these patients, and in addition can detect increased antisaccade errors and memory-guided saccade errors, reflecting cognitive impairment.

### Presymptomatic individuals

Presymptomatic carriers of HD-causing mutations have increased saccade latency<sup>70</sup> and latency variability, as well as impaired saccade suppression, shown by increased number of antisaccade errors and memory-guided errors. These impairments in saccade suppression can be demonstrated in the antisaccade paradigm in which saccades are made to a peripheral target instead of the target's opposite (mirror) location, or in the memory-guided paradigm, in which saccades are initiated prematurely to the target.<sup>63,67,71</sup> Antisaccade errors are most frequent in presymptomatic individuals who are closest to the onset of overt disease,<sup>8</sup> and the number of antisaccade errors correlates with the estimated time to onset of clinical symptoms,<sup>71</sup> although prosaccade latency might also correlate with the estimated time to symptom onset.<sup>70</sup> Increased variability of memory-guided saccade latency and the number of premature saccades (that is, timing errors) also correlate with a decreased time to onset of clinical symptoms.<sup>72</sup> Functional MRI scans suggest that impaired performance on antisaccade tasks in presymptomatic individuals with HD-causing mutations might be due to perverted activity in the presupplementary motor cortex and dorsal anterior cingulate cortex, both of which are involved in error detection.<sup>73</sup>

In summary, eye movements seem to be normal in clinical examination of presymptomatic individuals, but laboratory recordings can nonetheless reveal prolonged saccade latency, as well as errors in antisaccade and memory-guided saccade eye movements (Table 1).

### Disease progression

In a large longitudinal study<sup>8</sup> involving 123 patients with early HD and 123 presymptomatic carriers of HD

mutations, patients with manifest disease showed a decline in prosaccade (that is, reflexive saccade) latency precision over 12 months, whereas presymptomatic mutation carriers did not.<sup>10</sup> After 2 years, the amplitude of the primary prosaccade became increasingly variable in the symptomatic patients, but no significant change in amplitude was reported in presymptomatic individuals, irrespective of how close they were thought to be to clinical onset of symptoms.<sup>9</sup> However, the results of a smaller study suggested reflexive saccade latencies increased over 3 years in both presymptomatic individuals and patients with HD.<sup>74</sup> Although antisaccade and memory-guided saccades are abnormal in both presymptomatic individuals and patients with overt HD, the robust nature of the changes observed in reflexive saccades make this feature the most reliable oculomotor marker of progression to overt disease in individuals with presymptomatic HD. Longitudinal studies in large cohorts are needed to confirm whether measures of saccade characteristics are suitable markers of the onset of overt HD in presymptomatic individuals and of the progression of HD after onset of symptoms.

## The dementias

### Frontotemporal dementia

The three phenotypes of frontotemporal dementia (FTD) are behavioural variant, semantic dementia and progressive nonfluent aphasia (PNFA). Patients with PSP, corticobasal degeneration or FTD with motor neuron disease (FTD-MND), however, can also present with an FTD phenotype.<sup>75</sup> One study showed that all patients with a clinical diagnosis of one of the three FTD phenotypes had normal reflexive saccades, in contrast to patients with AD or corticobasal syndrome (in whom saccade latency was prolonged), and patients with PSP (in whom reflexive saccades were hypometric and of slow velocity).<sup>7</sup> Another study, however, demonstrated increased reflexive saccade latency in patients with behavioural variant FTD, as well as a tendency for these patients to make early saccades.<sup>76</sup> Patients with FTD and PNFA, but not those with semantic dementia, have increased errors on antisaccade tasks,<sup>7,76</sup> which are also observed in patients with AD, corticobasal syndrome or PSP. All patients with FTD phenotypes—but not those with AD, corticobasal syndrome or PSP—usually have normal self-correction of errors.<sup>7</sup> Reflexive saccades seem to be normal in patients with autopsy-proven FTD and TDP-43 neuropathology, whereas those with tau pathology have reduced horizontal saccade velocity and gain. These differences enable differentiation of patients with TDP-43 FTD from those with non-tau FTD or AD.<sup>48</sup>

In general, eye movement abnormalities in patients with FTD phenotypes depend on the brain regions affected by the disease rather than the intrinsic neuropathology. Thus, when the degenerative processes underlying dementia encompass the frontal and parietal lobes, as in patients with AD, saccades are delayed and saccade suppression errors are increased. When parietal regions are spared, as in patients with FTD, reflexive saccades are normal and saccade suppression errors are

**Table 2** | Eye movement characteristics in SCAs

Abnormality	SCA1	SCA2	SCA3	SCA6	SCA7*	SCA15	SCA17	Friedreich ataxia
Increased square wave jerks	–	–	+	(+)*	–	ND	–	(+++)
Gaze-evoked nystagmus	+	–	++	(+++)	±	++	±	+
Positional downbeat nystagmus	–	–	–	(+++)	ND	ND	ND	ND
Impaired smooth pursuit	+	±	++	+++	–	++	(++)	++
Decreased saccade velocity	(++)	(+++)	±	–	(+++)	–	–	±
Hypermetric saccades	+	–	±	(++) <sup>§</sup>	–	±	±	+
Hypometric saccades	±	–	++	+	–	±	(++)	±
Supranuclear gaze palsy	±	±	++	–	(++)	ND	++	–
Hypoactive vestibulo-ocular reflex	+	–	++	±	–	(±)	–	(+++)
Hyperactive vestibulo-ocular reflex	–	–	–	+	–	–	(++)	–

Features in brackets are characteristic of the condition. \*With pigmentary retinopathy. †Square wave jerks are synchronous with downbeat nystagmus. §Prominent downwards deviation during horizontal saccades. Abbreviations: –, not present; ±, present in some patients; +, mild; ++, moderate; +++, marked; ND, not determined; SCA, spinocerebellar ataxia.

increased but appropriately corrected. When parietal and frontal lobes are both spared, as in patients with semantic dementia, no increase in saccade suppression errors occurs (Table 1).

**Alzheimer disease**

Clinical oculomotor assessment in patients with AD may identify abnormalities in eye movements, but these are neither universally present nor specific to patients with AD. For example, confrontational oculomotor testing of patients with AD may show evidence of visual grasp reflex abnormalities on the antisaccade test,<sup>77</sup> but this is not a consistent finding and can occur in non-AD dementia. As for dementia in general, however, laboratory tests for oculomotor abnormalities in patients with AD using saccade tasks that probe cognitive impairment are more revealing than is clinical assessment (Table 1).

Four main types of saccade abnormalities have been consistently identified by laboratory tests in patients with AD: gaze-fixation instability, prolonged latency of reflexive and—especially—voluntary saccades, visual grasp reflex disturbances, and uncorrected errors in antisaccade performance.<sup>50,77–84</sup> Hypometria of reflexive and predictive saccades is also frequent.<sup>50,79,81,82,85</sup> The number of antisaccade errors,<sup>7,77–81</sup> especially uncorrected antisaccade errors,<sup>7,78,80</sup> correlates with the severity of dementia. Smooth pursuit gain is impaired in patients with AD, but this is a nonspecific feature.<sup>50,82</sup> Eye movements in patients with mild cognitive impairment have not been studied extensively. Saccades are generally normal in such patients,<sup>84</sup> although increased latency in a reflexive saccade overlap task has been reported in patients with mild amnesic cognitive impairment compared with age-matched healthy controls.<sup>83</sup>

In summary, clinical examination of eye movements in patients with dementia can reveal several key features that point to a specific diagnosis (Table 1, Figure 3): slow saccades might suggest PSP or HD; marked saccade hypometria and increased number of square wave jerks in conjunction with slow saccades are highly suggestive of PSP; substantial delay in initiation of saccades

(saccade apraxia) might suggest corticobasal syndrome or HD. Errors in direction on the clinical antisaccade test are common to most types of dementia except semantic dementia. Laboratory tests of eye movements can provide additional useful information to help distinguish between the various dementia phenotypes. Prolonged reflexive saccade latency suggests a possible diagnosis of AD or corticobasal syndrome. Increased antisaccade errors is indicative of frontal disease, and increased uncorrected antisaccade errors suggests additional parieto-occipital disease, although none of these abnormalities is specific enough to be diagnostic in the absence of other findings.

**Other neurodegenerative diseases**

**Motor neuron disease**

Eye movements in patients with MND are generally considered to be normal. Some patients with MND, however, have PSP-type eye movements with slowed vertical saccades and vertical supranuclear gaze palsy.<sup>86–89</sup> These patients are likely to have had bulbar symptoms at disease onset<sup>86</sup> and/or to develop rapidly progressive disease.<sup>90</sup> Patients with autopsy-proven FTD-MND and TDP-43 neuropathology, but without bulbar symptoms at disease onset, have normal saccade velocity.<sup>48</sup> The severity of oculomotor abnormalities in patients with MND might, therefore, reflect the burden of TDP-43 pathology.<sup>87,91</sup> In the laboratory, testing of saccade performance has revealed increased latency and error rates of memory-guided saccades and antisaccades, which is indicative of frontal lobe impairment, in patients with MND.<sup>92</sup> Increased square wave jerks associated with frontal lobe dysfunction has also been reported in these patients.<sup>92,93</sup> Reduced gain of smooth pursuit can also be present in patients with MND,<sup>87</sup> but this is not a disease-specific finding.

**Spinocerebellar ataxias**

Most spinocerebellar ataxias (SCAs) are polyglutamine disorders (as are HD, dentatorubropallidoluysian atrophy and spinobulbar muscular atrophy), in which the size of



the polyglutamine expansion influences the patient's age at onset and severity of disease.<sup>94</sup> Eye movement changes in patients with SCAs might be expected, therefore, to also correlate with the number of polyglutamine repeats.

Eye movement abnormalities are common in patients with SCA and reflect the combination of pure cerebellar degeneration and involvement of other brain regions (Table 2). For example, patients with SCA6 have classic cerebellar oculomotor abnormalities, such as gaze-evoked nystagmus, downbeat nystagmus (especially positional downbeat nystagmus<sup>95</sup>), and impaired smooth pursuit.<sup>95–97</sup> Eye-movement recordings obtained in the dark reveal synchronous square wave jerks and downbeat nystagmus.<sup>98</sup> Similarly, oculomotor changes in patients with SCA15, including horizontal gaze-evoked nystagmus and impaired smooth pursuit,<sup>99</sup> reflect mostly cerebellar pathology. The oculomotor hallmark of SCA2 is slow saccades,<sup>100,101</sup> which is indicative of brainstem pathology.<sup>102</sup> The velocity of saccades correlates with polyglutamine repeat size in patients with SCA2.<sup>100</sup> Patients with SCA1, SCA3, SCA17 and Friedreich ataxia have a mixture of cerebellar, brainstem and supratentorial eye movement abnormalities that do not necessarily correlate with polyglutamine repeat size.<sup>97,103–105</sup> Detailed examination of oculomotor function revealed gaze-evoked nystagmus in five of 15 patients with SCA17. Compared to healthy controls, SCA17 patients in this study also had marked impairment of smooth pursuit, hyperactive VOR, hypometric reflexive saccades of normal velocity, and a considerable increase in the error rates for memory-guided prosaccades and antisaccades.<sup>105</sup> The frequency of these oculomotor errors correlated with disease duration and severity, but not with the number of polyglutamine repeats.

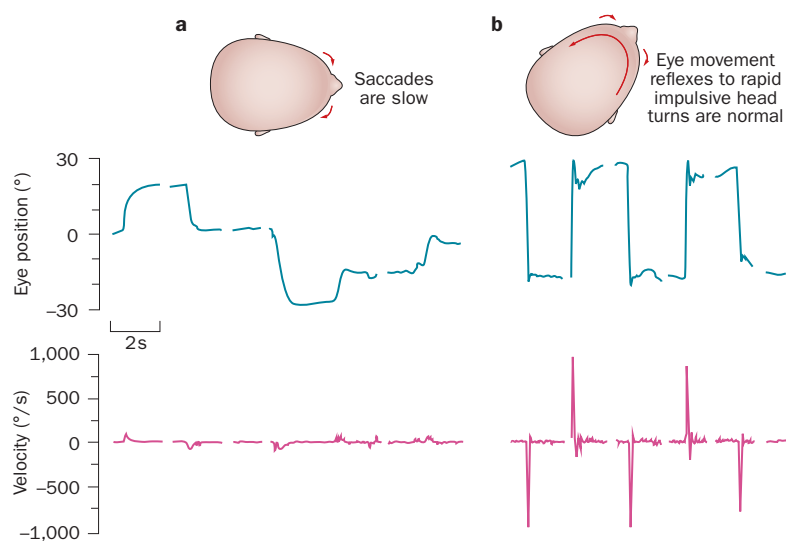
Some SCAs are associated with characteristic oculomotor features that are not commonly seen in the other SCAs, which can greatly assist diagnosis (Table 2). Thus, SCA2 is characterized by remarkably slowed saccades<sup>100</sup> with preserved VOR (Figure 4),<sup>97</sup> SCA1 by moderately slowed saccades,<sup>97,104</sup> Friedreich ataxia by a severely compromised VOR plus abundant square wave jerks,<sup>103</sup> SCA6 by positional downbeat nystagmus plus other cerebellar oculomotor signs,<sup>95,97</sup> and SCA7 by early and slowed saccades, as well as supranuclear gaze palsy in association with a pigmentary retinopathy.<sup>106–108</sup>

### Presymptomatic spinocerebellar ataxia

In contrast to HD, few studies of oculomotor abnormalities have been conducted in presymptomatic carriers of SCA-causing mutations, even though a majority of these disorders have an autosomal dominant mode of inheritance. In a study of 54 carriers of SCA2-associated mutations, the reduction in the velocity of 60° saccades correlated with the length of CAG repeats and estimated time to onset of clinical symptoms.<sup>109</sup>

### Eye movements as biomarkers

The common age-related neurodegenerative disorders are accompanied by oculomotor abnormalities, some of which are apparent on clinical examination, whereas



**Figure 4** | Horizontal saccade abnormalities in a patient with spinocerebellar ataxia type 2. **a** | Saccades are slow and of prolonged duration. The top trace indicates eye position as the patient followed a target that jumped either left (trace moves upwards) or right (trace moves downwards). The peak saccade velocity (lower trace) was drastically reduced: normal values are several hundred degrees per second for movements of this size. This finding is thought to reflect pathology that directly affects excitatory burst neurons in the paramedian pontine reticular formation of the brainstem. **b** | This region is bypassed in the vestibulo-ocular reflex, however, as the abducens nucleus is stimulated directly. Reflex eye movements in response to rapid impulsive head-turning (upper trace) were accordingly of normal velocity in this patient, with peak velocities (lower trace) greatly exceeding those of saccades. In each trace, blank sections correspond to deletions of blink artefacts due to frequent blepharospasm.

others—especially in those with cognitive impairment as the dominant feature—are most readily detected in laboratory recordings of eye movements. Eye movements are easily and painlessly recorded, and the resulting traces provide precise and objective data. In an era in which reliable noninvasive markers of disease are being called for, an important question is whether these disease-associated oculomotor changes are sufficiently sensitive and specific to be used for diagnostic purposes, and whether their association with relevant disease features is sufficiently robust to enable their use in tracking disease progression over time. Surprisingly, few studies have addressed these vital questions

To be considered as potential diagnostic markers, oculomotor abnormalities must be stable enough to enable repeat acquisition in the short term. In an electro-oculographic study of over 40 healthy individuals, the reliability of test–retest comparisons was similar in recordings obtained within the same session, and repeated after 1 week and 2 years (averaged  $r = 0.75$  and  $0.55$  for smooth pursuit gain and saccade latency, respectively). These observations indicated stability of eye movement measures over time, despite some intraindividual variability with recurrent testing.<sup>110</sup> In healthy individuals, in whom assessment of eye movements during seven different saccade tasks was carried out once every 4 weeks—twice in the morning and twice in the afternoon—saccade accuracy and the number of inappropriate reflexive saccades (prosaccade errors)

during the antisaccade task were not consistent over time. Other key parameters (smooth pursuit gain, saccadic intrusions during fixation, latency and velocity of reflexive and voluntary saccades, accuracy of reflexive saccades) were consistent—being both reliable over time and repeatable in the short term.<sup>111</sup> Antisaccade latency and the antisaccade error rate were repeatable in a small study of patients with HD and in controls, in traces recorded 1 month apart.<sup>112</sup>

Oculomotor abnormalities with potential as markers of disease stage or progression must show changes over time that correlate closely with other disease features in the medium and long term. The ease and precision of measuring saccades suggests that changes in these eye movements could be candidates for objective biomarkers of disease stage, progression and response to therapy. After deep brain stimulation of the subthalamic nucleus in patients with PD, improvements in eye movement abnormalities (reduced saccade latency and gain) have been reported across a number of visual tasks.<sup>113–116</sup> Only one study in patients with PD reported little effect of this treatment on oculomotor measures, in contrast to a striking improvement in somatomotor symptoms.<sup>28</sup> Studies that examined the effects of dopaminergic medications on eye movements in patients with PD have reported inconsistent results: such treatment reduced saccade latency, prolonged saccades, or had no effect, and had similarly varied effects on the amplitude of saccades.<sup>117</sup>

A useful biomarker of disease stage should reflect underlying brain function. A study of MRI voxel-based morphometry showed that prolonged saccade latency correlated with atrophy in the frontal eye fields in patients with PD.<sup>30</sup> In dementia, increased antisaccade errors is indicative of frontal lobe disease, and the extent of this increase might be useful as a marker of disease progression. Although eye movement abnormalities in patients with dementia are not specific enough for diagnostic purposes, they correlate with the severity of disease and cognitive impairment, suggesting that saccade abnormalities could be markers of dementia status and disease progression. Furthermore, saccade abnormalities in presymptomatic carriers of mutations that cause autosomal dominant disorders, such as HD and some SCAs, correlate with genetic factors that influence disease severity and/or estimated time to clinical onset of disease.

Further studies including large numbers of patients with a range of neurodegenerative diseases need to be

carried out before a cogent argument can be made for advocacy of oculomotor features as biomarkers of neurodegenerative disease.

## Conclusions

Clinical examination of eye movements can be a valuable—and sometimes essential—aid to clinicians in diagnosis of neurodegenerative disorders, especially for diseases with subcortical features, such as PSP, corticobasal syndrome and SCA2. Laboratory recordings of oculomotor abnormalities, particularly those derived from saccade tasks that involve various cognitive demands, show particular promise for probing both motor and cognitive function in patients with neurodegenerative diseases. Indeed, saccade characteristics could potentially be developed as markers of both disease status and progression, particularly in types of dementia that have a cortical component.

Certain saccade tasks have been used in the past 3 years to track disease status in presymptomatic HD mutation carriers and patients with overt HD,<sup>8–10</sup> but their role as valid biomarkers of disease status in HD and other neurodegenerative disorders has yet to be convincingly established. Further research is needed to provide evidence that eye movement measurements are robust, reliable and repeatable in individuals over time. Nevertheless, we can be optimistic that oculomotor abnormalities will prove to be valuable for more purposes than simply to indicate the presence of neurodegeneration. In the next few years, eye movement recordings are likely to be increasingly used to define disease status and monitor the severity of symptoms, particularly in clinical trials of new neuroprotective or disease-modifying therapies.

## Review criteria

We searched the PubMed database from 1995 and personal files for papers relating to “eye movements” or “saccades” or “oculomotor”, and “neurodegenerative”, and “Parkinson”, and “progressive supranuclear palsy” and “multiple system atrophy” and “corticobasal” and “spinocerebellar” and “Huntington” and “dementia” and “Alzheimer” and “frontotemporal dementia” and “motor neuron disease” and “ALS”. We also searched the reference lists of papers identified in the above search and reference lists in selected books. Only original articles in English were considered for this Review.

1. Bridgeman, B. Conscious vs unconscious processes: the case of vision. *Theory Psychology* **2**, 73–88 (1992).
2. Deubel, H. & Schneider, W. X. Delayed saccades, but not delayed manual aiming movements, require visual attention shifts. *Ann. NY Acad. Sci.* **1004**, 289–296 (2003).
3. Aarsland, D. in *Cognitive Impairment and Dementia in Parkinson's Disease* (ed. Emre, M.) 5–14 (Oxford University Press, Oxford, 2010).
4. Anderson, T. *et al.* Oculomotor function in multiple system atrophy: clinical and laboratory features in 30 patients. *Mov. Disord.* **23**, 977–984 (2008).
5. Chen, A. L. *et al.* The disturbance of gaze in progressive supranuclear palsy: implications for pathogenesis. *Front. Neurol.* **1**, 147 (2010).
6. Hellmuth, J. *et al.* Multicenter validation of a bedside antisaccade task as a measure of executive function. *Neurology* **78**, 1824–1831 (2012).
7. Garbutt, S. *et al.* Oculomotor function in frontotemporal lobar degeneration, related disorders and Alzheimer's disease. *Brain* **131**, 1268–1281 (2008).
8. Tabrizi, S. J. *et al.* Biological and clinical manifestations of Huntington's disease in the longitudinal TRACK-HD study: cross-sectional analysis of baseline data. *Lancet Neurol.* **8**, 791–801 (2009).
9. Tabrizi, S. J. *et al.* Potential endpoints for clinical trials in premanifest and early Huntington's disease in the TRACK-HD study: analysis of 24 month observational data. *Lancet Neurol.* **11**, 42–53 (2012).
10. Tabrizi, S. J. *et al.* Biological and clinical changes in premanifest and early stage Huntington's disease in the TRACK-HD study: the 12-month longitudinal analysis. *Lancet Neurol.* **10**, 31–42 (2011).
11. Munoz, D. P., Dorris, M. C., Pare, M. & Everling, S. On your mark, get set: brainstem circuitry

- underlying saccadic initiation. *Can. J. Physiol. Pharmacol.* **78**, 934–944 (2000).
12. Deubel, H. in *Attention and Performance XVII: Cognitive Regulation of Performance* (eds Gopher, D. & Koriati, A.) 697–721 (MIT Press, Cambridge, MA, 1999).
  13. Liu, P. & Basso, M. A. Substantia nigra stimulation influences monkey superior colliculus neuronal activity bilaterally. *J. Neurophysiol.* **100**, 1098–1112 (2008).
  14. Terao, Y. *et al.* Initiation and inhibitory control of saccades with the progression of Parkinson's disease—changes in three major drives converging on the superior colliculus. *Neuropsychologia* **49**, 1794–1806 (2011).
  15. MacAskill, M. R. *et al.* The influence of motor and cognitive impairment upon visually-guided saccades in Parkinson's disease. *Neuropsychologia* **50**, 3338–3347 (2012).
  16. Bronstein, A. M. & Kennard, C. Predictive ocular motor control in Parkinson's disease. *Brain* **108**, 925–940 (1985).
  17. Crawford, T. J., Goodrich, S., Henderson, L. & Kennard, C. Predictive responses in Parkinson's disease: manual keypresses and saccadic eye movements to regular stimulus events. *J. Neurol. Neurosurg. Psychiatry* **52**, 1033–1042 (1989).
  18. Ventre, J., Zee, D. S., Papageorgiou, H. & Reich, S. Abnormalities of predictive saccades in hemi-Parkinson's disease. *Brain* **115**, 1147–1165 (1992).
  19. O'Sullivan, S. S. *et al.* Clinical outcomes of progressive supranuclear palsy and multiple system atrophy. *Brain* **131**, 1362–1372 (2008).
  20. Chambers, J. M. & Prescott, T. J. Response times for visually guided saccades in persons with Parkinson's disease: a meta-analytic review. *Neuropsychologia* **48**, 887–899 (2010).
  21. Mosimann, U. P. *et al.* Saccadic eye movement changes in Parkinson's disease dementia and dementia with Lewy bodies. *Brain* **128**, 1267–1276 (2005).
  22. Matsumoto, H. *et al.* Small saccades restrict visual scanning area in Parkinson's disease. *Mov. Disord.* **26**, 1619–1626 (2011).
  23. Clark, U. S., Neargarder, S. & Cronin-Golomb, A. Visual exploration of emotional facial expressions in Parkinson's disease. *Neuropsychologia* **48**, 1901–1913 (2010).
  24. Anastasopoulos, D., Ziavra, N., Savidou, E., Bain, P. & Bronstein, A. M. Altered eye-to-foot coordination in standing parkinsonian patients during large gaze and whole-body reorientations. *Mov. Disord.* **26**, 2201–2211 (2011).
  25. Carpenter, M. G. & Bloem, B. R. A new twist on turning movements in Parkinson's disease patients. *Mov. Disord.* **26**, 2151–2153 (2011).
  26. Lohnes, C. A. & Earhart, G. M. Saccadic eye movements are related to turning performance in Parkinson disease. *J. Parkinsons Dis.* **1**, 109–118 (2011).
  27. Hely, M. A., Reid, W. G., Adena, M. A., Halliday, G. M. & Morris, J. G. The Sydney multicenter study of Parkinson's disease: the inevitability of dementia at 20 years. *Mov. Disord.* **23**, 837–844 (2008).
  28. Pinkhardt, E. H. *et al.* Eye movement impairments in Parkinson's disease: possible role of extradopaminergic mechanisms. *BMC Neurol.* **12**, 5 (2012).
  29. van Stockum, S., MacAskill, M. R., Anderson, T. J. & Dalrymple-Alford, J. C. Don't look now or look away: two sources of saccadic disinhibition in Parkinson's disease? *Neuropsychologia* **46**, 3108–3115 (2008).
  30. Pernecky, R. *et al.* Saccadic latency in Parkinson's disease correlates with executive function and brain atrophy, but not motor severity. *Neurobiol. Dis.* **43**, 79–85 (2011).
  31. Nakashima, H. *et al.* An autopsied case of dementia with Lewy bodies with supranuclear gaze palsy. *Neural. Res.* **25**, 533–537 (2003).
  32. Kapoula, Z. *et al.* Spread deficits in initiation, speed and accuracy of horizontal and vertical automatic saccades in dementia with lewy bodies. *Front. Neurol.* **1**, 138 (2010).
  33. Gilman, S. *et al.* Second consensus statement on the diagnosis of multiple system atrophy. *Neurology* **71**, 670–676 (2008).
  34. Rascol, O. *et al.* Square wave jerks in parkinsonian syndromes. *J. Neurol. Neurosurg. Psychiatry* **54**, 599–602 (1991).
  35. Linder, J., Wenngren, B. I., Stenlund, H. & Forsgren, L. Impaired oculomotor function in a community-based patient population with newly diagnosed idiopathic parkinsonism. *J. Neurol.* **259**, 1206–1214 (2012).
  36. Rascol, O. *et al.* Abnormal ocular movements in Parkinson's disease. Evidence for involvement of dopaminergic systems. *Brain* **112**, 1193–1214 (1989).
  37. Stell, R. & Bronstein, A. M. in *Movement Disorders 3* (eds Marsden, C. D. & Fahn, S.) 88–113 (Butterworth-Heinemann Ltd, Oxford, 1994).
  38. Arpa, J. *et al.* Electro-oculogram in multiple system and late onset cerebellar atrophies. *Rev. Neurol.* **23**, 969–974 (1995).
  39. Rascol, O. J., Clanet, M., Senard, J. M., Montastruc, J. L. & Rascol, A. Vestibulo-ocular reflex in Parkinson's disease and multiple system atrophy. *Adv. Neurol.* **60**, 395–397 (1993).
  40. Lee, J. Y. *et al.* Perverved head-shaking and positional downbeat nystagmus in patients with multiple system atrophy. *Mov. Disord.* **24**, 1290–1295 (2009).
  41. Williams, D. R. *et al.* Characteristics of two distinct clinical phenotypes in pathologically proven progressive supranuclear palsy: Richardson's syndrome and PSP-parkinsonism. *Brain* **128**, 1247–1258 (2005).
  42. Williams, D. R., Holton, J. L., Strand, K., Revesz, T. & Lees, A. J. Pure akinesia with gait freezing: a third clinical phenotype of progressive supranuclear palsy. *Mov. Disord.* **22**, 2235–2241 (2007).
  43. Williams, D. R. & Lees, A. J. Progressive supranuclear palsy: clinicopathological concepts and diagnostic challenges. *Lancet Neurol.* **8**, 270–279 (2009).
  44. Troost, B. T. & Daroff, R. B. The ocular motor defects in progressive supranuclear palsy. *Ann. Neurol.* **2**, 397–403 (1977).
  45. Bhidayasiri, R. *et al.* Pathophysiology of slow vertical saccades in progressive supranuclear palsy. *Neurology* **57**, 2070–2077 (2001).
  46. Vidailhet, M. *et al.* Eye movements in parkinsonian syndromes. *Ann. Neurol.* **35**, 420–426 (1994).
  47. Rivaud-Pechoux, S. *et al.* Longitudinal ocular motor study in corticobasal degeneration and progressive supranuclear palsy. *Neurology* **54**, 1029–1032 (2000).
  48. Boxer, A. L. *et al.* Saccade abnormalities in autopsy-confirmed frontotemporal lobar degeneration and Alzheimer disease. *Arch. Neurol.* **69**, 509–517 (2012).
  49. Litvan, I. *et al.* Clinical research criteria for the diagnosis of progressive supranuclear palsy (Steele-Richardson-Olszewski syndrome): report of the NINDS-SPSP international workshop. *Neurology* **47**, 1–9 (1996).
  50. Garbutt, S. *et al.* Abnormalities of optokinetic nystagmus in progressive supranuclear palsy. *J. Neurol. Neurosurg. Psychiatry* **75**, 1386–1394 (2004).
  51. Steele, J. C. Progressive supranuclear palsy. *Brain* **95**, 693–704 (1972).
  52. Altiparmak, U. E., Eggenberger, E., Coleman, A. & Condon, K. The ratio of square wave jerk rates to blink rates distinguishes progressive supranuclear palsy from Parkinson disease. *J. Neuroophthalmol.* **26**, 257–259 (2006).
  53. Rivaud-Pechoux, S., Vidailhet, M., Brandel, J. P. & Gaymard, B. Mixing pro- and antisaccades in patients with parkinsonian syndromes. *Brain* **130**, 256–264 (2007).
  54. Vidailhet, M. *et al.* Saccades and antisaccades in parkinsonian syndromes. *Adv. Neurol.* **80**, 377–382 (1999).
  55. Wadia, P. M. & Lang, A. E. The many faces of corticobasal degeneration. *Parkinsonism Relat. Disord.* **13** (Suppl. 3), S336–S340 (2007).
  56. Ling, H. *et al.* Does corticobasal degeneration exist? A clinicopathological re-evaluation. *Brain* **133**, 2045–2057 (2010).
  57. Vidailhet, M. & Rivaud-Pechoux, S. Eye movement disorders in corticobasal degeneration. *Adv. Neurol.* **82**, 161–167 (2000).
  58. Rottach, K. G., Riley, D. E., DiScenna, A. O., Zivotofsky, A. Z. & Leigh, R. J. Dynamic properties of horizontal and vertical eye movements in parkinsonian syndromes. *Ann. Neurol.* **39**, 368–377 (1996).
  59. Murray, R. *et al.* Cognitive and motor assessment in autopsy-proven corticobasal degeneration. *Neurology* **68**, 1274–1283 (2007).
  60. Lasker, A. G., Zee, D. S., Hain, T. C., Folstein, S. E. & Singer, H. S. Saccades in Huntington's disease: slowing and dysmetria. *Neurology* **38**, 427–431 (1988).
  61. Lasker, A. G. & Zee, D. S. Ocular motor abnormalities in Huntington's disease. *Vision Res.* **37**, 3639–3645 (1997).
  62. Peltsch, A., Hoffman, A., Armstrong, I., Pari, G. & Munoz, D. P. Saccadic impairments in Huntington's disease. *Exp. Brain Res.* **186**, 457–469 (2008).
  63. Golding, C. V., Danchavijit, C., Hodgson, T. L., Tabrizi, S. J. & Kennard, C. Identification of an oculomotor biomarker of preclinical Huntington disease. *Neurology* **67**, 485–487 (2006).
  64. Rupp, J. *et al.* Comparison of vertical and horizontal saccade measures and their relation to gray matter changes in premanifest and manifest Huntington disease. *J. Neurol.* **259**, 267–276 (2012).
  65. Winograd-Gurvich, C. T. *et al.* Hypometric primary saccades and increased variability in visually-guided saccades in Huntington's disease. *Neuropsychologia* **41**, 1683–1692 (2003).
  66. Leigh, R. J., Newman, S. A., Folstein, S. E., Lasker, A. G. & Jensen, B. A. Abnormal ocular motor control in Huntington's disease. *Neurology* **33**, 1268–1275 (1983).
  67. Blekher, T. *et al.* Saccades in presymptomatic and early stages of Huntington disease. *Neurology* **67**, 394–399 (2006).
  68. Patel, S. S., Jankovic, J., Hood, A. J., Jeter, C. B. & Sereno, A. B. Reflexive and volitional saccades: biomarkers of Huntington disease severity and progression. *J. Neurol. Sci.* **313**, 35–41 (2012).
  69. Henderson, T. *et al.* Inhibitory control during smooth pursuit in Parkinson's disease and Huntington's disease. *Mov. Disord.* **26**, 1893–1899 (2011).
  70. Turner, T. H. *et al.* Behavioral measures of saccade latency and inhibition in manifest and premanifest Huntington's disease. *J. Mot. Behav.* **43**, 295–302 (2011).

71. Hicks, S. L., Robert, M. P., Golding, C. V., Tabrizi, S. J. & Kennard, C. Oculomotor deficits indicate the progression of Huntington's disease. *Prog. Brain Res.* **171**, 555–558 (2008).
72. Rupp, J. *et al.* Progression in prediagnostic Huntington disease. *J. Neurol. Neurosurg. Psychiatry* **81**, 379–384 (2010).
73. Rupp, J. *et al.* Abnormal error-related antisaccade activation in premanifest and early manifest Huntington disease. *Neuropsychology* **25**, 306–318 (2011).
74. Antoniadis, C. A., Xu, Z., Mason, S. L., Carpenter, R. H. & Barker, R. A. Huntington's disease: changes in saccades and hand-tapping over 3 years. *J. Neurol.* **257**, 1890–1898 (2010).
75. Josephs, K. A. Frontotemporal dementia and related disorders: deciphering the enigma. *Ann. Neurol.* **64**, 4–14 (2008).
76. Burrell, J. R., Hornberger, M., Carpenter, R. H., Kiernan, M. C. & Hodges, J. R. Saccadic abnormalities in frontotemporal dementia. *Neurology* **78**, 1816–1823 (2012).
77. Currie, J., Ramsden, B., McArthur, C. & Maruff, P. Validation of a clinical antisaccadic eye movement test in the assessment of dementia. *Arch. Neurol.* **48**, 644–648 (1991).
78. Abel, L. A., Unverzagt, F. & Yee, R. D. Effects of stimulus predictability and interstimulus gap on saccades in Alzheimer's disease. *Dement. Geriatr. Cogn. Disord.* **13**, 235–243 (2002).
79. Boxer, A. L. *et al.* Medial versus lateral frontal lobe contributions to voluntary saccade control as revealed by the study of patients with frontal lobe degeneration. *J. Neurosci.* **26**, 6354–6363 (2006).
80. Crawford, T. J. *et al.* Inhibitory control of saccadic eye movements and cognitive impairment in Alzheimer's disease. *Biol. Psychiatry* **57**, 1052–1060 (2005).
81. Shafiq-Antonacci, R., Maruff, P., Masters, C. & Currie, J. Spectrum of saccade system function in Alzheimer disease. *Arch. Neurol.* **60**, 1272–1278 (2003).
82. Fletcher, W. A. & Sharpe, J. A. Saccadic eye movement dysfunction in Alzheimer's disease. *Ann. Neurol.* **20**, 464–741 (1986).
83. Yang, Q., Wang, T., Su, N., Xiao, S. & Kapoula, Z. Specific saccade deficits in patients with Alzheimer's disease at mild to moderate stage and in patients with amnesic mild cognitive impairment. *Age (Dordr.)* <http://dx.doi.org/10.1007/s11357-012-9420-z>.
84. Yang, Q. *et al.* Long latency and high variability in accuracy-speed of prosaccades in Alzheimer's disease at mild to moderate stage. *Dement. Geriatr. Cogn. Dis. Extra* **1**, 318–329 (2011).
85. Schewe, H. J., Uebelhack, R. & Vohs, K. Abnormality in saccadic eye movement in dementia. *Eur. Psychiatry* **14**, 52–53 (1999).
86. Donaghy, C. *et al.* Slow saccades in bulbar-onset motor neurone disease. *J. Neurol.* **257**, 1134–1140 (2010).
87. Donaghy, C., Thurtell, M. J., Piro, E. P., Gibson, J. M. & Leigh, R. J. Eye movements in amyotrophic lateral sclerosis and its mimics: a review with illustrative cases. *J. Neurol. Neurosurg. Psychiatry* **82**, 110–116 (2011).
88. Ohki, M. *et al.* Ocular abnormalities in amyotrophic lateral sclerosis. *Acta Otolaryngol. Suppl.* **511**, 138–142 (1994).
89. Averbuch-Heller, L., Helmchen, C., Horn, A. K., Leigh, R. J. & Buttner-Ennever, J. A. Slow vertical saccades in motor neuron disease: correlation of structure and function. *Ann. Neurol.* **44**, 641–648 (1998).
90. Leveille, A., Kiernan, J., Goodwin, J. A. & Antel, J. Eye movements in amyotrophic lateral sclerosis. *Arch. Neurol.* **39**, 684–686 (1982).
91. McCluskey, L. F. *et al.* Amyotrophic lateral sclerosis-plus syndrome with TAR DNA-binding protein-43 pathology. *Arch. Neurol.* **66**, 121–124 (2009).
92. Shaunak, S. *et al.* Oculomotor function in amyotrophic lateral sclerosis: evidence for frontal impairment. *Ann. Neurol.* **38**, 38–44 (1995).
93. Donaghy, C. *et al.* Ocular fixation instabilities in motor neurone disease. A marker of frontal lobe dysfunction? *J. Neurol.* **256**, 420–426 (2009).
94. Orr, H. T. & Zoghbi, H. Y. Trinucleotide repeat disorders. *Annu. Rev. Neurosci.* **30**, 575–621 (2007).
95. Yabe, I. *et al.* Positional vertigo and macroscopic downbeat positioning nystagmus in spinocerebellar ataxia type 6 (SCA6). *J. Neurol.* **250**, 440–443 (2003).
96. Gomez, C. M. *et al.* Spinocerebellar ataxia type 6: gaze-evoked and vertical nystagmus, Purkinje cell degeneration, and variable age of onset. *Ann. Neurol.* **42**, 933–950 (1997).
97. Buttner, N. *et al.* Oculomotor phenotypes in autosomal dominant ataxias. *Arch. Neurol.* **55**, 1353–1357 (1998).
98. Bour, L. J., van Rootselaar, A. F., Koelman, J. H. & Tijssen, M. A. Oculomotor abnormalities in myoclonic tremor: a comparison with spinocerebellar ataxia type 6. *Brain* **131**, 2295–2303 (2008).
99. Marelli, C. *et al.* SCA15 due to large ITPR1 deletions in a cohort of 333 white families with dominant ataxia. *Arch. Neurol.* **68**, 637–643 (2011).
100. Velazquez-Perez, L. *et al.* Saccade velocity is controlled by polyglutamine size in spinocerebellar ataxia 2. *Ann. Neurol.* **56**, 444–447 (2004).
101. Wadia, N. *et al.* A clinicogenetic analysis of six Indian spinocerebellar ataxia (SCA2) pedigrees. The significance of slow saccades in diagnosis. *Brain* **121**, 2341–2355 (1998).
102. Geiner, S., Horn, A. K., Wadia, N. H., Sakai, H. & Buttner-Ennever, J. A. The neuroanatomical basis of slow saccades in spinocerebellar ataxia type 2 (Wadia-subtype). *Prog. Brain Res.* **171**, 575–581 (2008).
103. Fahey, M. C. *et al.* Vestibular, saccadic and fixation abnormalities in genetically confirmed Friedreich ataxia. *Brain* **131**, 1035–1045 (2008).
104. Burk, K. *et al.* Autosomal dominant cerebellar ataxia type I: oculomotor abnormalities in families with SCA1, SCA2, and SCA3. *J. Neurol.* **246**, 789–797 (1999).
105. Hubner, J. *et al.* Eye movement abnormalities in spinocerebellar ataxia type 17 (SCA17). *Neurology* **69**, 1160–1168 (2007).
106. Enevoldson, T. P., Sanders, M. D. & Harding, A. E. Autosomal dominant cerebellar ataxia with pigmentary macular dystrophy. A clinical and genetic study of eight families. *Brain* **117**, 445–460 (1994).
107. Oh, A. K., Jacobson, K. M., Jen, J. C. & Baloh, R. W. Slowing of voluntary and involuntary saccades: an early sign in spinocerebellar ataxia type 7. *Ann. Neurol.* **49**, 801–804 (2001).
108. Thurtell, M. J. *et al.* Two patients with spinocerebellar ataxia type 7 presenting with profound binocular visual loss yet minimal ophthalmoscopic findings. *J. Neuroophthalmol.* **29**, 187–191 (2009).
109. Velazquez-Perez, L. *et al.* Saccade velocity is reduced in presymptomatic spinocerebellar ataxia type 2. *Clin. Neurophysiol.* **120**, 632–635 (2009).
110. Iacono, W. G. & Lykken, D. T. Two-year retest stability of eye tracking performance and a comparison of electro-oculographic and infrared recording techniques: evidence of EEG in the electro-oculogram. *Psychophysiology* **18**, 49–55 (1981).
111. Roy-Byrne, P., Radant, A., Wingerson, D. & Cowley, D. S. Human oculomotor function: reliability and diurnal variation. *Biol. Psychiatry* **38**, 92–97 (1995).
112. Blekher, T. *et al.* Test-retest reliability of saccadic measures in subjects at risk for Huntington disease. *Invest. Ophthalmol. Vis. Sci.* **50**, 5707–5711 (2009).
113. Rivaud-Péchoix, S. *et al.* Improvement of memory guided saccades in parkinsonian patients by high frequency subthalamic nucleus stimulation. *J. Neurol. Neurosurg. Psychiatry* **68**, 381–384 (2000).
114. Sauleau, P. *et al.* Subthalamic stimulation improves orienting gaze movements in Parkinson's disease. *Clin. Neurophysiol.* **119**, 1857–1863 (2008).
115. Temel, Y., Visser-Vandewalle, V. & Carpenter, R. H. Saccadometry: a novel clinical tool for quantification of the motor effects of subthalamic nucleus stimulation in Parkinson's disease. *Exp. Neurol.* **216**, 481–489 (2009).
116. Temel, Y., Visser-Vandewalle, V. & Carpenter, R. H. Saccadic latency during electrical stimulation of the human subthalamic nucleus. *Curr. Biol.* **18**, R412–R414 (2008).
117. Pinkhardt, E. H. & Kassubek, J. Ocular motor abnormalities in Parkinsonian syndromes. *Parkinsonism Relat. Disord.* **17**, 223–230 (2011).

#### Author contributions

T. J. Anderson and M. R. MacAskill contributed equally to researching data for the article, discussion of the content, writing the article, and to review and/or editing of the manuscript before submission.